

Intraventricular Hemorrhage in the Neonate

NICU Night Team Curriculum

Objectives

- To describe the epidemiology and risk factors of IVH
- To understand the anatomy and pathophysiology involved in IVH
- To demonstrate the grading system of IVH
- To comprehend the sequelae of high-grade IVH

Case

- Two day old 750g 25 ⁴/₇ week GA male born by vertex, vaginal delivery to a mother who received good PNC after rupture of membranes 10 hours prior to delivery and precipitous labor. Otherwise healthy pregnancy.
- Medications during pregnancy:
 - Prenatal vitamin
 - Ampicillin during labor for unknown GBS status x 2 doses
 - Betamethasone x 2
- Delivery Course:
 - NSVD, nuchal cord x1, easily reduced
 - Apgars: 5¹, 8⁵
 - Initially given Positive pressure ventilation then intubated
 - Given one dose of surfactant in delivery room
 - Transferred to ICN and placed on SIMV with volume control

Case (cont.)

- Vital signs remained stable through Days 0 and 1
- Fluids given through TPN at total fluids: 120 cc/kg/d
- Patient started on Ampicillin and Gentamicin until blood culture negative x 48 hours
- Chemistries stable, checked q12h
- Admission hemoglobin was 12.4, but dropped to 8.6 at 48 hours of life

WHAT IS THE DIFFERENTIAL DIAGNOSIS FOR ACUTE DROP IN HEMOGLOBIN IN A NEONATE?

Differential Diagnosis

- Blood Loss
 - Cephalohematoma
 - Intraventricular Hemorrhage
 - Subdural Hemorrhage
 - Subgaleal
 - Liver Rupture
 - Spleen Rupture
 - Pulmonary Hemorrhage
- Iatrogenic
- Hemolysis Secondary to Infection
 - Sepsis
 - Viral
 - Bacterial
 - TORCH

In our patient, ultrasound
revealed:
Grade III IVH

Epidemiology and Risk Factors

- Among extremely premature babies:
 - IVH rates have declined from 50-80% in 1980s to current rate of 10-15%¹
 - Continues to be a significant problem as improved survival of extremely premature infants has resulted in more survivors with this injury

What are the major risk factors for IVH?

1. Volpe JJ. Neurology of the Newborn, 4th Edition, WB Saunders, Philadelphia 2001. p 428

Risk Factors for IVH

1. Prematurity:

- Occurs most frequently in infants born <32 weeks or <1500g
- Incidence is 26% for infants weighing 501-1500g²
- The highest prevalence is in the least mature infants
- Mortality: ~15%² (worse prognosis with increasing severity)

2. Timing:

- Virtually all IVH in premature infants occurs in first five days²
- 50, 25, and 15% on the first, second and third day, respectively²
- By the end of the first week, 90% of hemorrhages can be detected³

3. Other Risk Factors³:

- Intrapartum asphyxia
- Chorioamnionitis
- Hypoxemia
- Hypercarbia
- Pneumothorax/Pulmonary Hemorrhage
- Maternal fertility treatment

1. Vermont Oxford Network. 2002. table 1.2

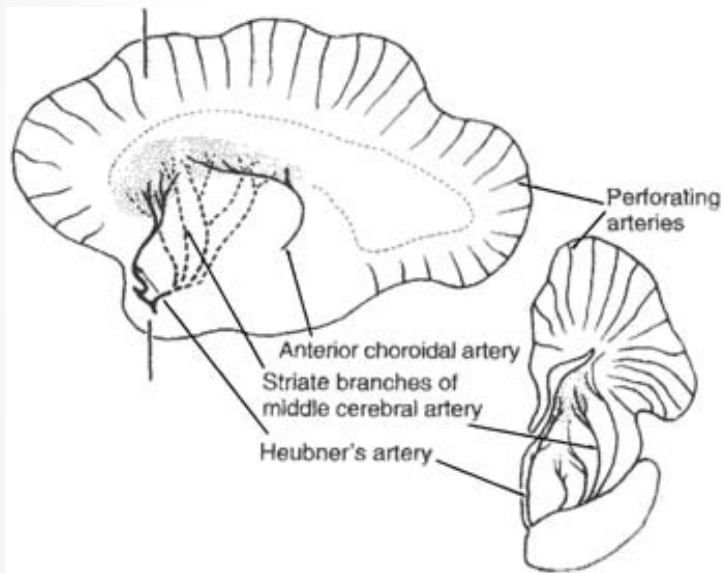
2. Volpe JJ. Neurology of the Newborn, 4th Edition, WB Saunders, Philadelphia 2001. p 428

3. McCrea HJ and Ment LR. 2008. Clinical Perinatology (35(4): 777-vii

Anatomy and Pathophysiology

The Germinal Matrix in Premature Infants¹

- The germinal matrix is a highly cellular layer in the subependymal, subventricular zone that gives rise to neurons and glia during development
- The immature germinal matrix is highly vascularized by fragile microvessels
- In response to hypertension, hypoxia, hypercapnia or acidosis, cerebral blood flow increases placing stress on vasculature
- Hemorrhage in preterm babies often begins in the germinal matrix and may extend to ventricular system



Arterial supply to the subependymal germinal matrix at 29 weeks gestation²

1. McCrea HJ and Ment LR. 2008. Clinical Perinatology (35(4): 777-vii

2. Image from Hambleton G, and Wigglesworth JS. 1976. Archives of Diseases in Childhood 51(9): 651.

How is the diagnosis of IVH made?

- Cranial Ultrasound is the screening method of choice
- Up to half of infants with IVH may be asymptomatic
- According to the American Academy of Neurology and the Practice Committee of Child Neurology Society:
 - Routine ultrasound should be performed on all infants <30weeks gest age
 - Screening should be performed a 7-14 days and repeated at 36-40 weeks
- CT or MRI offer no advantage in detection of IVH

•

•

Grading IVH

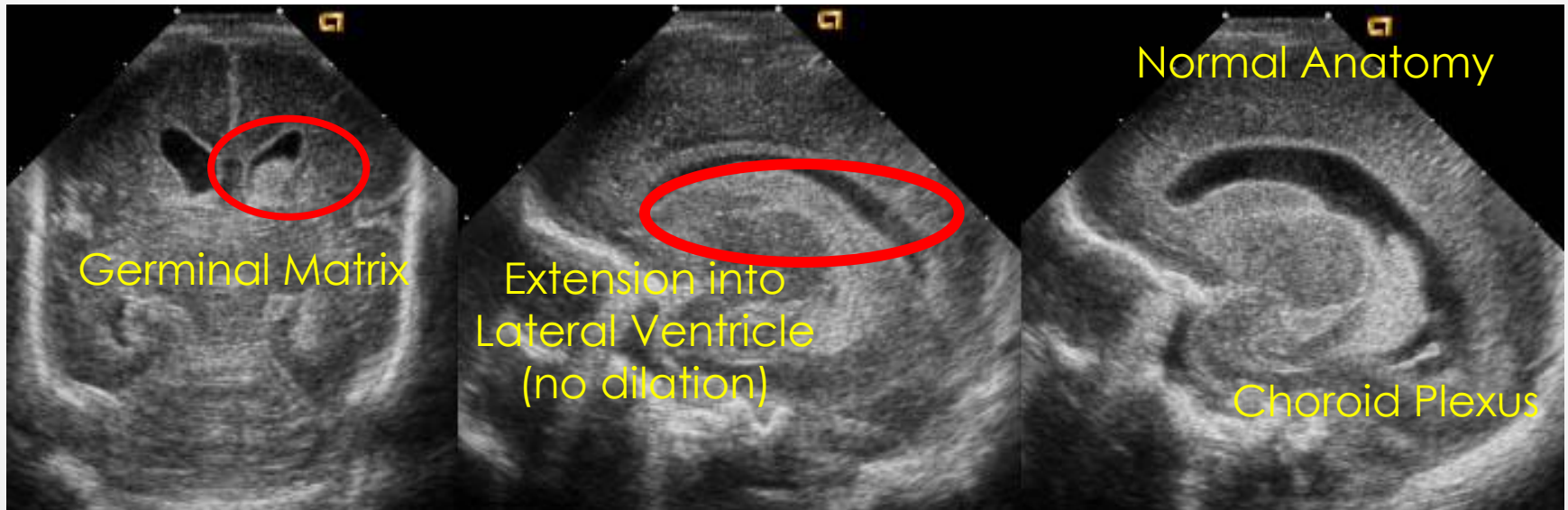
Intracranial hemorrhage

Classification according to Papile

- Grade 1.** Hemorrhage limited to subependymal matrix
- Grade 2.** Hemorrhage extending into ventricular system, < 50%, without acute ventriculomegaly
- Grade 3.** Hemorrhage extending into ventricular system, with acute dilatation because of flooding of 50% or more of one or both lateral ventricles
- Grade 4.** Hemorrhage grade 1, 2 or 3 with extension into brain tissue

Grade That Hemorrhage!!

1. Where is the hemorrhage?
2. Name the Anatomy
3. Grade the Hemorrhage



Grade II Hemorrhage

Extension into lateral ventricle without dilation

Name the Sequelae of Intraventricular Hemorrhage

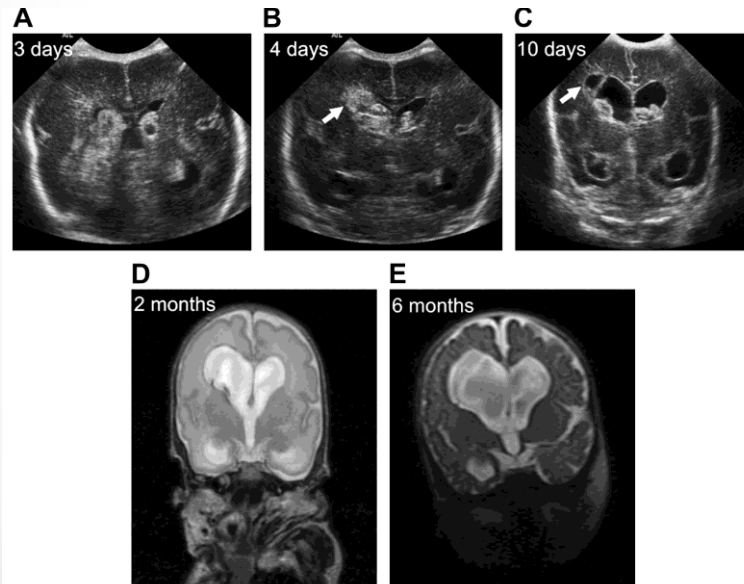
...

- 1.
- 2.
- 3.
- 4.
- 5.

Sequelae of IVH

1. Posthemorrhagic Hydrocephalus

- Usually presents with rapid increases in head circumference
- Signs and symptoms may not be evident for several weeks due to compliance of neonatal brain
- Believed to be due to impaired CSF reabsorption following the inflammation related to blood in the CSF
- No proven effective interventions have been described to date

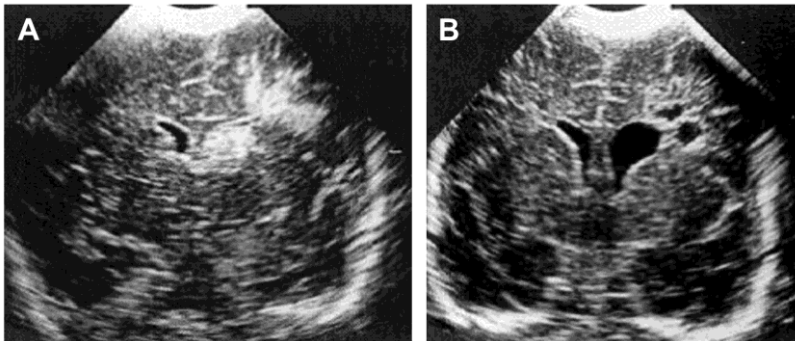


Serial cranial ultrasounds and MRI studies from a preterm male infant born at 24 weeks of gestation. The initial diagnosis of Grade 3 IVH at age 3 days (panel A) was followed by parenchymal involvement of hemorrhage, or Grade 4 IVH, on postnatal day 4 (arrow, panel B). A cranial ultrasound performed on day 10 because of increasing occipitofrontal head circumference and full fontanel revealed bilateral ventriculomegaly, residual intraventricular blood and a developing porencephaly (arrow, panel C). MRI study at 2 months demonstrated ventriculomegaly (panel D). Because of excessive increase in head circumference and increasing spasticity, the patient underwent third ventriculostomy following MRI scan at age 6 months (panel E).

Sequelae of IVH

2. Periventricular Leukomalacia (PVL)

- Classic white matter abnormality following IVH
- Attributed to profound and long-lasting decreases in CSF
- PVL may progress to porencepholy (Greek for “hole in the brain”)
- Depending on severity, may lead to spastic dysplasia, visual defects, or cognitive impairment



Serial cranial ultrasounds of a 30 week preterm male with Grade 3 IVH and hemorrhagic PVL at age 10 days (panel A). Repeat ultrasound 3 weeks later demonstrated unilateral ventriculomegaly and periventricular cystic cavities consistent with PVL (panel B).

Sequelae of IVH

3. Seizures
4. Cerebral Palsy
5. Mental Retardation

Risk for major neurological deficits:

Grade I: 5-9%	Grade II: 11-15%
Grade III: 30-40%	Grade IV: 50-70%

Preventive Strategies

Many potential pharmacologic interventions have been studied, though few are currently in wide use*

Pharmacologic Agent	Proposed Mechanism
Phenobarbital	Stabilize blood pressure and free radical production
Indomethacin	Promotes microvasculature maturation; blunt fluctuations in BP and cerebral blood flow
Ibuprofen	Improve autoregulation and cerebral blood flow
Pavulon	Prevent asynchronous breathing in ventilated newborns; secondary BP stabilization
Ethamsylate	Promote platelet adhesion, increase capillary basement membrane stability
• Vitamin E	Free Radical Protection <small>*see notes section for more details</small>

Conclusion

- IVH remains a common problem of extreme prematurity
- Hemorrhage often arises from vasculature of the germinal matrix
- Severe neurodevelopmental sequelae can arise and is associated with increasing severity of the hemorrhage
- Very few, if any, good preventive strategies are available